



# Catheter Placement Technique

*This material is provided for educational purposes and represents the technique used by the following surgeon. Catheter placement is provided for guidance only and is subject to the individual expertise, experience and school-of-thought of the surgeon placing the catheter. This protocol is not to be construed as I-Flow's specific recommendation.*

**Posterior Cervical  
Fusion**

Charles Park, MD

Neurosurgeon  
Franklin Square Hospital

◆

Baltimore, MD

Drug Manufacturers' Recommended Dose	
<u>Maximum 24 Hour Dose</u>	
<u>Drug</u>	<u>Maximum</u>
Bupivacaine (Marcaine®, Sensorcaine®)	400 mg
Levobupivacaine (Chirocaine®)	695 mg
Ropivacaine (Naropin®)	770 mg
<u>Maximum Total Dose</u>	
<i>24 hour dose not specified</i>	
Lidocaine (Xylocaine)	300 mg
All local anesthetics are without epinephrine and manufacturer recommendations should be regarded as guidelines for use in adults.	

**Sample Protocol**

**Pump Used:**  
PM013: 270 ml x 2 ml/hr

**Drugs in Pump:**  
175 ml of 0.5% Marcaine plain

**Catheter Placement:**  
Above the fascia in the subcutaneous tissue

**Postoperative Bolus Technique:**  
5 ml of 0.5% Marcaine plain

**Catheter Securement Technique:**  
Dermabond and Tegaderm™

**Additional Post-Op Pain Medications:**  
Morphine administered through I.V. as needed or Percocet.

**CAUTIONS:**

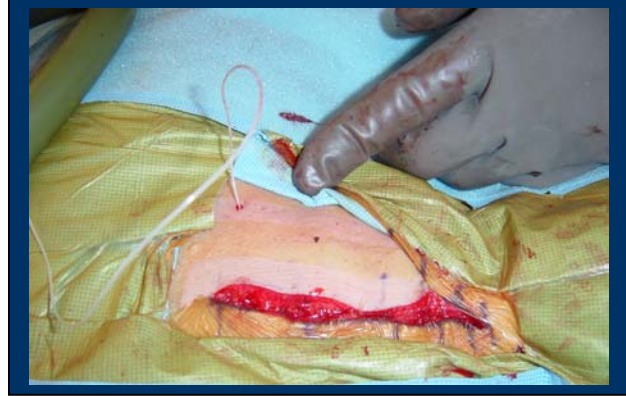
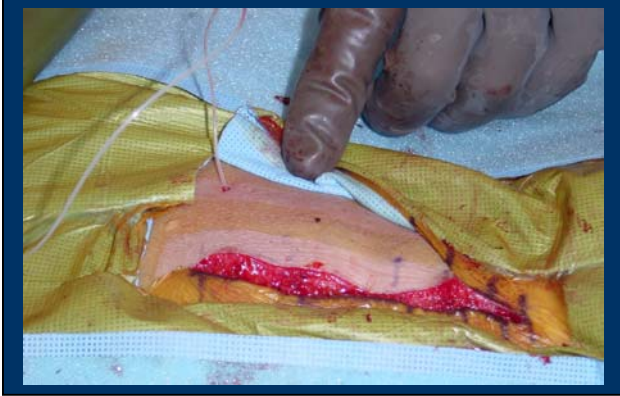
- Medications used with this system should be administered in accordance with instructions provided by the drug manufacturer (see guidelines above). Surgeon is responsible for prescribing drug based on each patient's clinical status (e.g., age, body weight, disease state of patient).
- Vascoconstrictors such as Epinephrine or Adrenaline are not necessary and may not be recommended for continuous infusions.
- Refer to ON-Q PainBuster Directions for Use for full instructions on using the ON-Q PainBuster System.

# Posterior Cervical Fusion

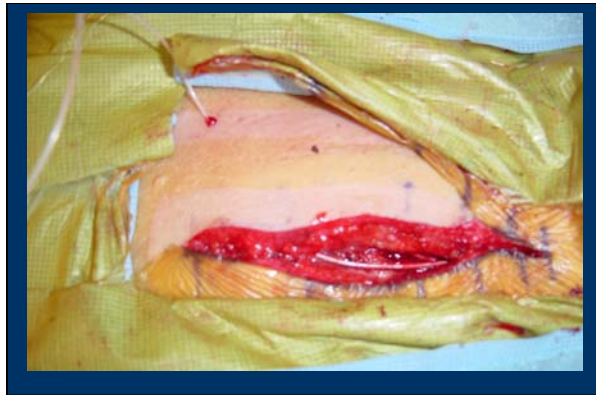Dr. Charles Park, Neurosurgeon, Baltimore, MD

*These illustrations are for general guidance only and not intended to be interpreted as precise anatomical illustrations.*

## Puncture Site



## Placement



## Securement

